

# Effect of Pamidronate Treatment in Children with Polyostotic Fibrous Dysplasia of Bone

HORACIO PLOTKIN, FRANK RAUCH, LEONID ZEITLIN, CRAIG MUNNS, ROSE TRAVERS, AND FRANCIS H. GLORIEUX

*Genetics Unit, Shriners Hospital for Children, Québec, Canada H3G 1A6; and the Departments of Surgery and Pediatrics, McGill University, Montréal, Québec, Canada H3H 1P3*

**Intravenous infusions with the bisphosphonate compound pamidronate decrease bone pain and reportedly can lead to refilling of dysplastic lesions in adults with fibrous dysplasia (FD) of bone. Here we describe the effects of this treatment approach in 18 children and adolescents (age at start of therapy, 6.2–17.5 yr; eight girls) with polyostotic FD, who received pamidronate for 1.2–9.1 yr (median, 3.8 yr). Treatment cycles with pamidronate (1–1.5 mg/kg·d on 3 consecutive days) were given every 4 months. Levels of serum alkaline phosphatase and urinary collagen type I N-telopeptide were elevated at baseline and decreased continuously during the first 3 yr of**

**therapy. There was no radiographic evidence of filling of lytic lesions or thickening of the bone cortex surrounding the lesions in any patient. Histochemical results in dysplastic bone tissue of patients receiving pamidronate (n = 7; time of therapy, 1.4–4.8 yr) were similar to those of patients without medical therapy (n = 9). No serious side effects were noted. In conclusion, pamidronate therapy appears to be safe in children and adolescents with polyostotic FD. However, we found no clear evidence that pamidronate has an effect on dysplastic lesions in such patients. (*J Clin Endocrinol Metab* 88: 4569–4575, 2003)**

**F**IBROUS DYSPLASIA (FD) of bone is a congenital, non-hereditary skeletal disorder. The disease affects both sexes equally and usually is diagnosed in childhood or adolescence. FD occurs when bone marrow cells are affected by somatic activating mutations of the gene encoding the  $\alpha$ -subunit of the stimulatory G protein,  $G_s \alpha$  (1). The mutation has a mosaic distribution and results in locally increased stimulation of adenylyl cyclase and overproduction of cAMP. In bone mesenchymal cells, the downstream effects of the mutation include increased production of c-fos protein and IL-6 (1, 2). At the bone tissue level, FD is characterized by dysplastic lesions that consist of abnormal fibrous tissue in the marrow space intertwined with poorly oriented, irregular trabeculae of woven bone (1).

On x-rays, dysplastic lesions frequently have a lytic or cystic appearance. The surrounding bone cortex is reduced in thickness, and sometimes the entire bone is widened. Radioisotopic bone scans usually disclose increased uptake in affected areas. Systemic indices of bone turnover are often elevated, especially if lesions are widespread (3). Frequently, hypophosphatemia is present, which is probably caused by a circulating phosphaturic factor (3, 4).

The natural evolution of the disorder is clearly quite variable (1). Lesions may remain stable for decades, but can also progress relentlessly, leading to multiple fractures and severe bone deformities. The disease progress appears to be more rapid in the growing skeleton (5).

Treatment of FD has long been largely confined to orthopedic surgery, consisting of preventive measures (curettage, bone grafting, internal fixation of long bones) and management of fractures (6). However, an open-label study of treat-

ment with the bisphosphonate compound pamidronate yielded promising results in adults (7). Bone pain decreased, and refilling of bone lesions was observed radiologically in a number of patients. These positive effects of pamidronate—an antiresorptive agent—may come as a surprise in a disease that is caused by a mutation in cells of the osteoblast lineage. However, there is some evidence for increased bone resorptive activity within dysplastic lesions (8–10).

Recent observations suggest that pamidronate therapy also has some beneficial effect in children with FD (11–13). A decrease of bone pain and of markers of bone metabolism was reported. These studies comprised two, four, and nine pediatric patients, respectively, and had a relatively short follow-up period. In the present report, we describe clinical, biochemical, radiological and histological effects of pamidronate therapy in a group of 18 children and adolescents with polyostotic FD.

## Patients and Methods

### Patients

The present report includes all of the 18 patients (8 girls, 10 boys) with polyostotic FD who received cyclical iv pamidronate therapy at the Montreal Shriners Hospital for at least 1 yr (range, 1.2–9.1 yr, during the observation period between June 1992 and March 2002). Age at the start of therapy ranged from 6.2–17.5 yr (Table 1). The diagnosis was based on the presence of radiologically detectable bone lesions at two or more sites. In addition, bone tissue from affected skeletal locations could be obtained from 11 patients and genetic studies were performed (14). In each case, the presence of FD-specific heterozygous mutations in codon 201 of the  $G_s \alpha$  gene was confirmed.

Seven patients were hypophosphatemic (serum inorganic phosphorus levels between 0.89 and 0.99 mmol/liter; reference range, 1.23–1.62 mmol/liter) at the start of pamidronate therapy. No attempt was made to correct hypophosphatemia, because none of the patients had signs of rickets (15).

Three girls and one boy had skin and/or endocrinologic manifestations and were therefore diagnosed as having McCune-Albright syn-

Abbreviations: BMC, Bone mineral content; FD, fibrous dysplasia; NTX, N-telopeptide of type I collagen; vBMD, volumetric bone mineral density.

**TABLE 1.** Clinical characteristics of patients at the start of treatment

No.	Sex	Age (yr)	Involved sites	Mobility score	Diagnosis	Duration of treatment follow-up (yr)
1	M	17.5	Panostotic	2	PFD	9.1
2	M	11.8	Skull (occipital and parietal); R humerus; R and L femur, tibia, fibula	4	PFD	7.5
3	F	7.6	L radius; R femur; R tibia; R metatarsal II	4	MAS	1.2
4	M	11.6	Skull; face; R scapula; R humerus; R ulna; R thumb; L femur; L tibia	4	PFD	7.0
5	M	11.2	R femur; R fibula	4	PFD	1.9
6	F	10.5	Skull; L humerus; R humerus; R radius; R hand phalanges	2	MAS	5.6
7	M	13.9	R and L humerus, ulna, radius; ribs; R and L femur, tibia, fibula	2	PFD	3.9
8	M	6.2	Panostotic	0	PFD	3.6
9	M	4.2	L orbita, L metacarpals, L femur, L tibia, L metatarsals	4	MAS	3.7
10	F	8.8	R femur, R tibia; R metatarsal II–IV	4	PFD	1.3
11	M	11.5	R and L femur, tibia, fibula	4	PFD	4.2
12	F	9.8	R and L femur	0	PFD	3.7
13	F	11.1	R and L femur	4	PFD	2.0
14	M	13.1	L humerus; L ulna; L phalanges; R and L femur, tibia	4	PFD	6.6
15	F	9.2	Skull; R and L femur; L tibia; L fibula	4	PFD	6.2
16	F	8.5	R femur, R fibula	4	PFD	2.6
17	M	4.0	R and L femur, tibia	4	PFD	4.1
18	F	6.4	R femur, R tibia	4	MAS	3.3

R, Right; L, left; PFD, polyostotic fibrous dysplasia; MAS, McCune-Albright syndrome.

drome (Table 1). The three girls had precocious puberty that had been treated before the start of pamidronate. Treatment of precocious puberty was surgical in one case (excision of an autonomous ovarian cyst) and included aromatase inhibitors (testolactone) in the two others. The boy had only café-au-lait spots. In the other 14 patients, endocrinologic evaluation did not reveal abnormalities and no symptoms of endocrine dysfunction developed during the course of follow-up. Eleven patients had sustained 1–14 fractures before treatment with pamidronate was started. Clinically, six patients had marked limb deformity, and two of them had panostotic disease (16). All patients presented with pain at the site of the lesions.

Mobility was evaluated for each child by physiotherapists experienced in the care of children with bone diseases. A 5-point score was used: 0, bed-wheelchair-bound; 1, walking with aids possible, but non-functional; 2, household walker, with/without aids; 3, neighborhood walker with/without aids; and 4, independent walker (17).

Informed consent was obtained in each instance from the legal guardian. The study protocol was approved by the ethics committee of the Shriners Hospital.

### Treatment

The treatment protocol was similar to the schedule that we have been using for the treatment of osteogenesis imperfecta (18). Pamidronate was administered iv on 3 consecutive days in all patients. The first 3-d cycle consisted of a dose of 0.5 mg/kg on d 1 and 1 mg/kg on d 2 and 3. In subsequent cycles, the dose was 1–1.5 mg/kg daily for 3 d, the dose depending on the perceived treatment success. Pamidronate cycles were repeated every 4 months, as the clinical effect of a treatment cycle (reduction of bone pain, increase in stamina) appeared to diminish after this time. Each dose was diluted in 0.9% saline solution and administered slowly over 4 h. Calcium and vitamin D intake was maintained adequately according to the recommended daily allowance in all patients. All patients underwent physiotherapy and occupational therapy evaluation and support, including exercises and design of special devices for transportation and sitting.

### Follow-up

Each patient was examined every 4 months. Biochemical measurements and bone densitometry were performed at every visit, and x-rays

of involved sites were taken at a yearly interval. According to the treatment protocol, iliac bone biopsies were to be performed before the start of treatment and after 2 yr of therapy. As the biopsy specimens were preferably obtained during elective orthopedic procedures, the actual timing of the biopsy could deviate from the treatment protocol. In patients who did not require orthopedic interventions, specimens were obtained under general anesthesia in a procedure performed exclusively for this purpose. Biopsies were not performed in patients who presented an elevated risk for anesthesia.

### Biochemistry

Serum total calcium, phosphate, creatinine and alkaline phosphatase activity were measured using colorimetric methods (Monarch; Instrumentation Laboratories Inc., Lexington, MA). Serum PTH concentrations (fragment 39–84) were determined by RIA (19). 25-OH vitamin D and 1,25-OH<sub>2</sub> vitamin D were measured with RIAs (25-hydroxyvitamin D and 1,25-dihydroxyvitamin D Osteo SP; Incstar Corp., Stillwater, MN). Urinary calcium and creatinine were quantified colorimetrically. The bone resorption marker urinary cross-linked N-telopeptide of type I collagen (NTX) was quantified by ELISA (Osteomark; Ostex, Seattle, WA) on the second void sample of the morning. Results for urinary NTX/creatinine ratios were compared with published reference data (20). Patients were fasting at the time of blood and urine sampling.

### Bone densitometry

Bone densitometry was performed in the anteroposterior direction at the lumbar spine (L1–L4) using a Hologic QDR 2000W or 4500A device (Hologic Inc., Waltham, MA). Volumetric bone mineral density (vBMD) was calculated as the ratio between bone mineral content (BMC) and the extrapolated external volume of the measured bones. This was done as described by Carter *et al.* (21) using the formula:

$$\text{vBMD} = \text{BMC}/(\text{projection area})^{1.5}$$

Age- and sex-specific mean values for projection area and vBMD in healthy children were calculated from published densitometric reference material (22). Results for BMC, projection area, and vBMD in FD patients were expressed as a percentage of these mean values for healthy children.

### Radiographic evaluation

For quantitative evaluation of dysplastic lesions, we compared x-rays that were obtained at the start of treatment to those from the last follow-up visit. Radiographs were screened for dysplastic lesions that were sufficiently well delimited to allow for measurement of lesion size. Five patients (patient 1, 2, 7, 8, and 11) did not have any well-circumscribed lesions and were excluded from this analysis. In the other patients, we determined maximal lesion length and width as well as cortical thickness at the middle of the lesion's length (Fig. 1). The inner border of the sclerotic rim surrounding a lesion was regarded as the limit of the lesion. To make up for effects of bone growth and technique-related differences in magnification, the width of a lesion was related to the width of the mid-shaft diaphysis of the same bone, and the length of the lesion was related to bone length. Cortical width at the site of the lesion was related to cortical width at the mid-shaft diaphysis of the same bone (Fig. 1).

### Bone biopsy and histomorphometry

Transiliac bone samples were collected on d 4 or 5 after dual labeling with demeclocycline (15–20 mg/kg·d taken orally during two 2-d periods separated by a 10-d free interval). Biopsy preparation and histomorphometric analyses were performed with the standard procedures used at the Shriners Hospital, as described previously (23). Measurements were carried out using a digitizing table with Osteomeasure software (Osteometrics Inc., Atlanta, GA). Nomenclature and abbreviations follow the recommendations of the American Society for Bone and Mineral Research (24). Specimens from FD patients were examined for the presence of a dysplastic fibrous lesion. Specimens with and without evidence for dysplastic tissue were analyzed separately (see *Results*). Results were compared with those of age-matched controls that were taken from our reference sample collection (23).

### Statistical analysis

Comparisons between two groups were performed using Student's unpaired *t* test or Mann-Whitney *U* test, as appropriate. Longitudinal differences between two time points within the same group of subjects

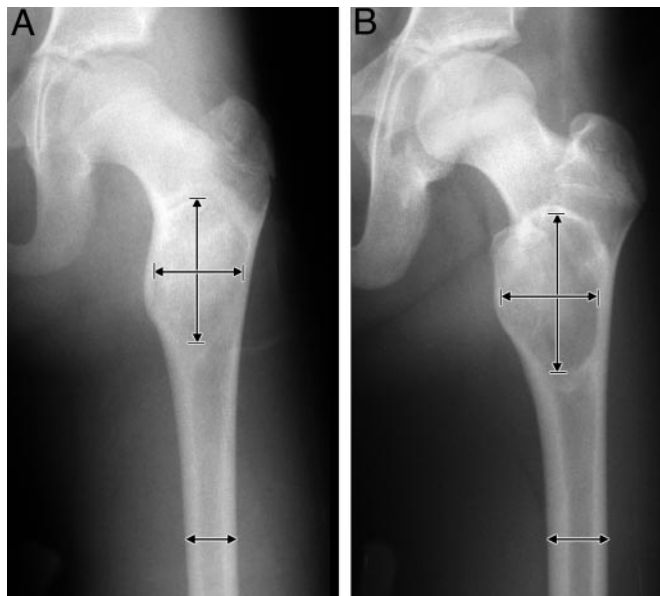


FIG. 1. Quantitative evaluation of dysplastic lesion size. Lesion length and width (arrows and short bars) as well as cortical thickness at the middle of the lesion's length (not indicated) were measured on x-rays. The width of each lesion was related to the width of the midshaft diaphysis of the same bone (arrow), and the length of the lesion was related to bone length (not indicated). Cortical width at the site of the lesion was related to cortical width at the midshaft diaphysis of the same bone. A, Proximal femur of patient 13 at the start of pamidronate treatment. B, After 2.0 yr of treatment.

were compared by paired *t* test or Wilcoxon's test, as appropriate. The difference of densitometric results from the mean value of healthy subjects was tested for significance using the one-sample *t* test. All tests were two-tailed, and throughout the study,  $P < 0.05$  was considered significant. These calculations were performed using the SPSS software, version 9.0 for Windows (SPSS Inc., Chicago, IL).

## Results

### Mineral metabolism

At baseline, serum total calcium levels, urinary calcium/creatinine ratios and serum PTH levels were within or very close to the reference range in all patients. Serum 25-OH vitamin D concentrations were moderately low in four patients (19–32 nmol/liter; reference range 34–91 nmol/liter). Serum 1,25-OH<sub>2</sub> vitamin D levels were low in seven patients (between 25 and 55 pmol/liter; reference range, 65–134 pmol/liter) and were elevated in two patients (207 and 213 pmol/liter).

During the first 3 d of the initial infusion cycle, total serum calcium dropped by  $0.32 \pm 0.04$  mmol/liter (mean  $\pm$  SE) to reach a nadir of  $2.04 \pm 0.02$  mmol/liter. Serum calcium had returned to baseline values by the time the patients were readmitted for the second infusion cycle 4 months later. Fluctuations in serum calcium were smaller during subsequent treatment cycles (decreases of  $0.23 \pm 0.03$  mmol/liter and  $0.21 \pm 0.02$  mmol/liter during the second and third cycles, respectively). Hypocalcemia was not associated with clinical symptoms and was treated with oral calcium supplements. In no case was iv calcium therapy required.

The decrease in serum calcium was associated with an increase in serum PTH levels. PTH reached values up to twice the upper limit of the reference range on the third day of the first infusion cycle. However, levels consistently returned to pretreatment results by the time of the next treatment cycle. The transient rise in PTH levels was associated with the expected transient decrease in serum phosphorus (by  $0.49 \pm 0.08$  mmol/liter) and an increase in 1,25-OH<sub>2</sub> vitamin D concentrations (by  $87 \pm 25\%$ ;  $n = 13$ ).

### Bone metabolism

Pretreatment alkaline phosphatase activity was above the age-related reference range in 17 of the 18 patients. Urinary NTX/creatinine ratios were above the age- and sex-specific 75th percentile in 12 patients (Fig. 2). On d 3 of the first infusion cycle, alkaline phosphatase and NTX/creatinine had decreased to  $85 \pm 3\%$  and  $51 \pm 8\%$  of the pretreatment value, respectively (in both cases  $P < 0.001$  for difference to pretreatment results). Thereafter, alkaline phosphatase levels remained stable during the 4 months until the patients returned for the second infusion, whereas NTX/creatinine ratios increased slightly (to  $67 \pm 6\%$  of the baseline result).

The long-term effects of pamidronate on bone metabolism were evaluated in the 13 patients who had received at least 3 yr of therapy (Fig. 3). Only those samples were used for this analysis that were obtained immediately before a treatment cycle. Both serum alkaline phosphatase and urinary NTX/creatinine remained persistently below the baseline level. After a rapid decrease in the first year of therapy, there was a continuous and less steep decline with time.

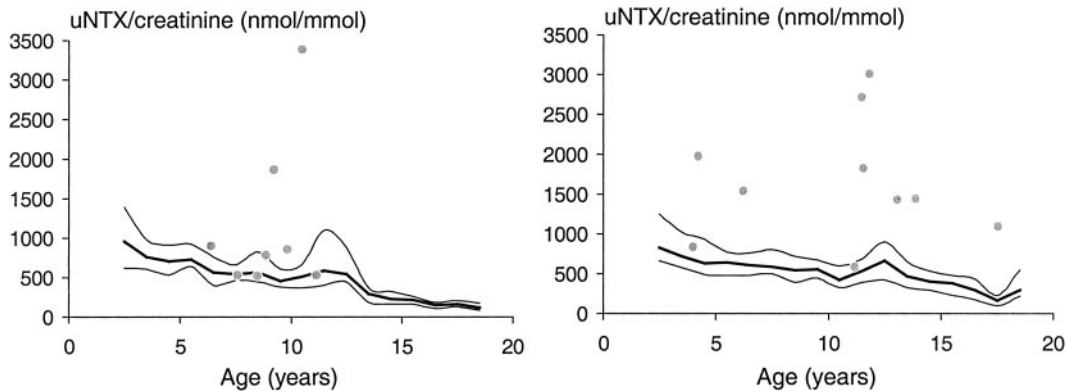


FIG. 2. Pretreatment urinary NTX/creatinine ratios in girls (*left panel*) and boys (*right panel*). Lines represent the 75th (*top*), 50th (*middle*), and 25th (*bottom*) percentile, respectively, of the reference range for healthy subjects (19).

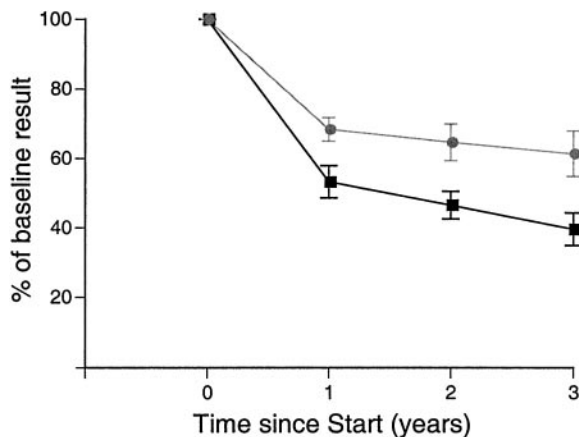


FIG. 3. Changes in serum alkaline phosphatase activity (*circles*) and urinary NTX/creatinine ratios (*squares*) during long-term pamidronate therapy ( $n = 13$  patients). This analysis used samples that were obtained just before the start of a new treatment cycle. All results obtained after the start of therapy are significantly different from the pretreatment values ( $P < 0.001$  in each case).

### Radiology

There was no clear evidence of refilling of lytic lesions. In contrast, some lesions clearly increased in size during pamidronate therapy (Fig. 4). In the 13 patients with well-delimited lesions, there was a significant increase in lesion width even after correction for the width of unaffected bone ( $P = 0.01$ ; Wilcoxon test). No significant changes were noted in lesion length related to bone length and in cortical width at the site of the lesion related to cortical width of unaffected bone ( $P > 0.1$  in both cases). Limb and spine deformities did not regress. None of the patients had radiological signs of rickets at any time.

The long-term effect of pamidronate therapy on the size, mass, and density of unaffected bone was evaluated in the 10 patients who had received at least 3 yr of therapy and who did not have radiological evidence of a dysplastic lesion at the lumbar spine (Fig. 5). Bone size, as judged from the anteroposterior vertebral projection area was below the reference mean value at baseline ( $P = 0.04$ ) but remained at a constant percentage of the value expected for age and sex. In contrast, BMC increased faster than in healthy children. These changes led to a significant increase in vBMD, which

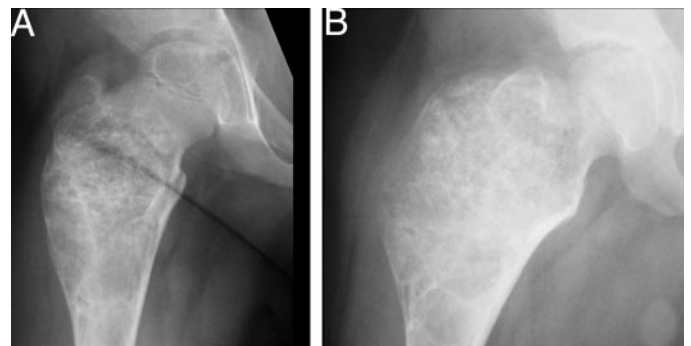


FIG. 4. Right proximal femur of patient 3 at the start of pamidronate treatment (A) and 1.2 yr later (B).

after 3 yr of treatment was 22% above the value expected for healthy children ( $P = 0.003$ ).

### Histomorphometry

The effect of pamidronate treatment on bone tissue was analyzed separately for dysplastic and unaffected bone. The results of pretreatment and treatment samples could not be analyzed in a longitudinal manner, because there was an insufficient number of specimen pairs consisting exclusively of affected or unaffected tissue, respectively. Therefore, histomorphometric data were evaluated in a cross-sectional fashion.

Iliac biopsy samples containing dysplastic bone tissue were obtained from nine patients who had not received pamidronate before biopsy and from seven patients who had been on pamidronate for a median time of 2.2 yr (Table 2; Fig. 6). Histomorphometric results were similar for treated and untreated patients. In particular, there was no detectable treatment effect on resorption parameters, and there was a similar accumulation of osteoid.

Iliac bone specimens containing only unaffected bone tissue could be obtained from 12 patients who had received pamidronate for a median of 2.0 yr (Table 3). These samples were used to assess treatment safety, in particular to search for evidence of a mineralization defect during pamidronate therapy. Compared with age-matched controls, samples from FD patients had lower osteoid thickness, mineralizing surface per bone surface and mineralizing surface per osteoid

surface. Mineral apposition rate and mineralization lag time were similar in the two groups. Three FD patients had prolonged mineralization lag time (above 25 d), but osteoid thickness was not increased in any patient. Thus, none of the patients fulfilled the histomorphometric criteria for osteomalacia (15).

### Growth

Four severely affected patients had stopped growing before the start of pamidronate therapy and were extremely short (height z-scores between  $-5.5$  and  $-9.9$ ). Figure 7 shows height data in patients who were still growing when entering the study. Pretreatment height was within normal limits for most of these children. In the 14 growing patients who completed 1 yr of therapy, there was no significant

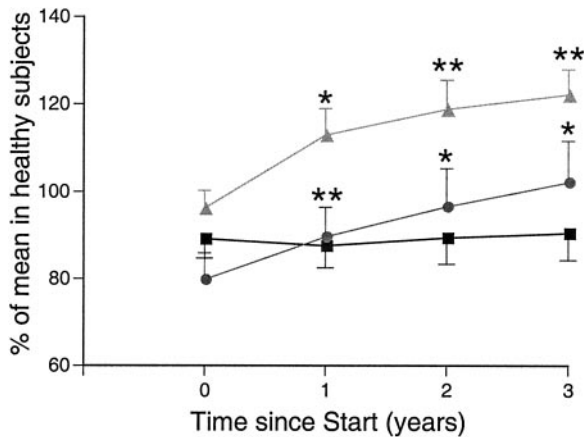


FIG. 5. Changes in lumbar spine BMC (circles), vBMD (triangles), and projection area (squares) during 3 yr of pamidronate treatment. Only patients without radiological evidence of spine involvement were included ( $n = 10$ ). All results are given as a percentage of the age- and sex-specific mean value in a healthy reference population. Asterisks indicate a significant difference to pretreatment values. \*,  $P < 0.05$ ; \*\*,  $P < 0.01$ .

TABLE 2. Histomorphometry of dysplastic bone tissue

	No.	Treated	No.	Untreated	<i>P</i>	Control ( $n = 12$ )
Age (yr)	7	$12.5 \pm 4.9$	9	$10.7 \pm 3.8$	0.42	$12.0 \pm 3.2$
Bone structure						
Bone volume per tissue volume (%)	7	$26.8 \pm 9.7$	9	$27.9 \pm 6.5$	0.80	$23.3 \pm 4.2$
Trabecular thickness ( $\mu\text{m}$ )	7	$95 \pm 50$	9	$94 \pm 29$	0.93	$143 \pm 22$
Trabecular number (per mm)	7	$3.0 \pm 0.6$	8	$3.0 \pm 0.9$	0.98	$1.6 \pm 0.2$
Bone formation						
Osteoid thickness ( $\mu\text{m}$ )	7	$13.0 \pm 5.8$	9	$17.7 \pm 7.9$	0.21	$6.6 \pm 1.7$
Osteoid surface per bone surface (%)	7	$74 \pm 16$	9	$71 \pm 15$	0.76	$26 \pm 10$
Osteoid volume per bone volume (%)	7	$26 \pm 22$	9	$32 \pm 19$	0.60	$2.5 \pm 1.1$
Osteoblast surface per bone surface (%)	6	$28 \pm 10$	7	$20 \pm 14$	0.32	$8 \pm 4$
Mineralizing surface per bone surface (%)	6	$19 \pm 7$	6	$18 \pm 6$	0.77	$13 \pm 5$
Mineral apposition rate ( $\mu\text{m}/\text{d}$ )	6	$0.78 \pm 0.22$	8	$0.75 \pm 0.27$	0.83	$0.87 \pm 0.09$
Bone formation rate per bone surface ( $\mu\text{m}^3 \cdot \mu\text{m}^{-2} \cdot \text{yr}^{-1}$ )	6	$60 \pm 42$	6	$56 \pm 32$	0.85	$43 \pm 17$
Bone resorption						
Osteoclast surface per bone surface (%)	7	$2.3 \pm 1.1$	9	$2.4 \pm 1.4$	0.91	$0.87 \pm 0.35$
Eroded surface per bone surface (%)	7	$14 \pm 10$	9	$17 \pm 6$	0.60	$16 \pm 5$

Specimens from patients on pamidronate therapy (for a median of 2.2 yr; range, 1.4–4.8 yr) are compared with those from patients who had not received medical therapy before biopsy. Values from age-matched healthy controls are shown for comparison.

Values are mean  $\pm$  SD or median (range). *P* values represent the significance of the difference between samples obtained from untreated and treated patients (*t* test).

change in height z-scores ( $P = 0.59$ , Wilcoxon test). Height z-scores also remained stable in the nine growing patients who received at least 3 yr of pamidronate therapy (median z-score at baseline:  $-1.4$ , range  $-8.1$  to  $0.4$ ; after 3 yr of therapy:  $-1.5$ , range  $-8.4$  to  $0.7$ ;  $P = 0.07$ ). Weight z-scores did not change significantly during this time ( $P = 0.26$ ).

### Clinical course

An acute phase reaction in the form of a flu-like syndrome developed in most patients during the first treatment cycle. The symptoms lasted for 24–48 h and resolved without complications. This reaction was similar to that noted in children with osteogenesis imperfecta (18).

During the follow-up period, seven patients had increasing coxa vara (shepherd's hook) requiring orthopedic surgery. Mobility score improved from 2 to 3 in two patients and remained unchanged in the others. Two patients sustained two fractures, five had one fracture and the remainder had no fractures during the observation period. Pamidronate treatment did not have an obvious effect on bone healing after fracture or osteotomy.

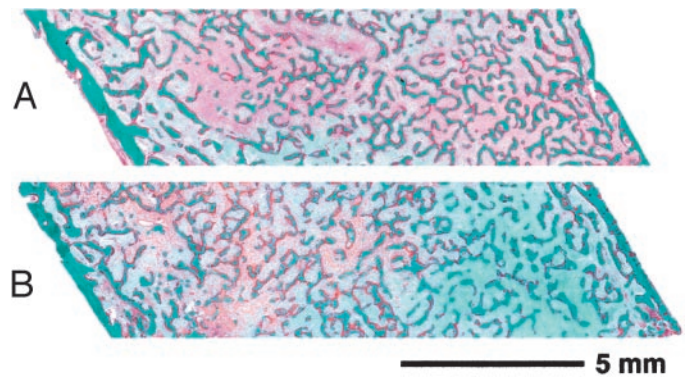


FIG. 6. Iliac bone biopsy specimens containing dysplastic bone tissue before (A) and after (B) 1.7 yr of pamidronate therapy (patient 13). There is no obvious difference between the two samples.

**TABLE 3.** Effect of pamidronate therapy on mineralization in unaffected bone tissue

	n	FD	n	Control	P
Age (yr)	12	11.8 ± 2.4	12	12.0 ± 3.2	0.88
Osteoid thickness (μm)	12	4.9 ± 1.8	12	6.6 ± 1.7	0.03
Osteoid surface per bone surface (%)	12	21 ± 17	12	26 ± 10	0.40
Mineralizing surface per bone surface (%)	10	7.7 ± 6.0	12	13.5 ± 5.2	0.03
Mineralizing surface per osteoid surface (%)	10	33 ± 20	12	54 ± 18	0.02
Mineral apposition rate (μm/d)	10	0.82 ± 0.19	12	0.87 ± 0.09	0.43
Mineralization lag time (d)	10	22 (9–112)	12	16 (9–23)	0.21

Specimens from patients on pamidronate therapy (for a median of 2.0 yr; range, 1.0–2.8 yr) are compared with those from healthy age-matched controls.

Values are mean ± SD or median (range). P values represent the significance of the difference between the two groups (*t* test or *U* test, as appropriate).

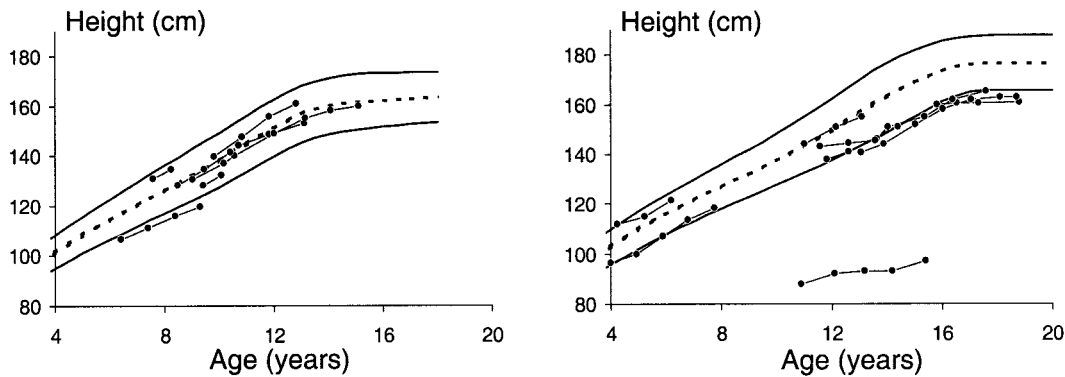


FIG. 7. Height development in growing girls (*left panel*) and boys (*right panel*) during 3 yr of pamidronate therapy. The 95th (*top*), 50th (*middle*), and 5th (*bottom*) percentiles of the reference range are also indicated.

At the time of last follow-up, eight patients continued to receive pamidronate therapy. Pamidronate was discontinued in 10 patients after a treatment period ranging from 1.2–7.5 yr. Six of these patients felt that there was no more benefit of treatment, and they are without medical therapy since. The four other patients were enrolled in a trial of oral alendronate, after dysplastic lesions had continued to progress under pamidronate.

### Discussion

In this observational study, we evaluated the effect of cyclical iv pamidronate therapy in children and adolescents with severe polyostotic FD. Although not quantitatively examined, pamidronate appeared to be effective in reducing bone pain, confirming earlier reports (7, 12, 13). However, we were unable to objectively demonstrate a positive therapeutic effect on the size or histological appearance of dysplastic lesions. This is consistent with the results of smaller series of pediatric FD patients, where no radiological evidence for refilling of dysplastic lesions was found (12, 13). Nevertheless, these results are somewhat disappointing, as Chapurlat *et al.* (7) had reported refilling of dysplastic lesions in about half of adult patients who underwent a similar treatment protocol.

It thus appears that there is a difference between the treatment effect in adults and in children. It is possible that FD lesions progress faster in young subjects than in adults and thus might be more difficult to control with medical therapy (5). The patients in our study may have been more severely affected than those of Chapurlat *et al.*, as suggested by the

considerable proportion of our patients who had hypophosphatemia. It can be speculated that pamidronate may have slowed down the expansion of lesions in our patients, even if it did not visibly improve them. This hypothesis can be tested only in a placebo-controlled study where subjects are closely matched for age and disease severity. It should be noted that the results reported in adults were not based on controlled studies either, leaving open the possibility that the reported refilling of dysplastic lesions reflected the natural evolution of the disorder rather than a true treatment effect.

One might assume that decreasing bone marker levels during pamidronate therapy indicate a slower activity of the dysplastic lesions. However, pamidronate does not specifically act on FD lesions, but also suppresses the turnover of unaffected bone tissue. It is difficult to judge whether changes in the levels of biochemical bone markers reflect more the effect of therapy on lesions or on unaffected bone. Our histomorphometric studies revealed decreased turnover in unaffected bone tissue during therapy, but did not demonstrate a treatment effect on the metabolic activity of dysplastic lesions.

Whereas the efficacy of pamidronate therapy is hard to prove, our observations suggest that this treatment approach is safe. Longitudinal growth was not affected, and lumbar spine bone size increased at a normal rate. This is consistent with our observations in patients with osteogenesis imperfecta (25, 26). The vBMD of unaffected lumbar spine vertebrae increased above the age- and sex-specific mean value but remained well below levels that are seen in osteopetrosis. Yet, one possible source of concern is the decreased bone

turnover of unaffected bone tissue. The implications of chronically low bone turnover in growing children are unknown at present.

The effect of therapy on bone mineralization is an important consideration, because one 13-yr-old FD patient in the series of Chapurlat *et al.* (7) developed rickets during pamidronate therapy. In the present study, hypophosphatemia was commonly found in the pretreatment evaluation, confirming recently published findings (3). None of our patients developed radiological signs of rickets, even though each treatment cycle led to a further transient decrease in serum inorganic phosphorus concentrations. Osteomalacia is part of the histological picture of a dysplastic lesion (27), but we have shown earlier that this is independent of systemic serum phosphorus levels (15). There was no indication of a systemic mineralization defect during pamidronate treatment, as there was no accumulation of osteoid in bone samples that did not contain dysplastic lesions. Quite to the contrary, osteoid thickness was low during pamidronate therapy. This probably reflects the decreased bone turnover, similar to what can be observed in patients with osteogenesis imperfecta who receive pamidronate (28).

In conclusion, pamidronate treatment of children and adolescents with severe forms of polyostotic FD appears to be safe and reduces bone pain. In that respect, pamidronate certainly is beneficial. However, we found no clear evidence that pamidronate has an effect on dysplastic lesions in such patients. Unfortunately, no form of medical therapy has been shown to yield any better results. Glucocorticoids and 1,25-OH<sub>2</sub> vitamin D have been proposed as therapeutic agents based on *in vitro* data but have not yet been put to clinical test (29, 30). It is possible that a different bisphosphonate or a combination of drugs will have a more marked effect on dysplastic lesions than pamidronate. There clearly is a need to explore new treatment options for children and adolescents with polyostotic FD.

### Acknowledgments

We thank Guy Charette and Josée Dépot for technical assistance with biopsy sample processing, and Mark Lepik for preparing the figures. We are indebted to Milan Bayer (Charles University, Prague, Czech Republic) for help in the preliminary stages of the study.

Received January 10, 2003. Accepted June 14, 2003.

Address all correspondence and requests for reprints to: Frank Rauch, Genetics Unit, Shriners Hospital for Children, 1529 Cedar Avenue, Montréal, Québec, Canada H3G 1A6. E-mail: frauch@shriners.mcgill.ca.

This study was supported by the Shriners of North America. C.M. is the Royal Children's Hospital Foundation/Woolworths Scholar.

Current address for H.P.: Inherited Metabolic Diseases Section, Children's Hospital and Department of Pediatrics, University of Nebraska, Omaha, Nebraska 68198-5430.

### References

- Schoenau E, Rauch F 2002 Fibrous dysplasia. *Horm Res* 57(Suppl 2):79–82
- Candeliere GA, Glorieux FH, Prud'homme J, St-Arnaud R 1995 Increased expression of the *c-fos* proto-oncogene in bone from patients with fibrous dysplasia. *N Engl J Med* 332:1546–1551
- Collins MT, Chebli C, Jones J, Kushner H, Consugar M, Rinaldo P, Wientroub S, Bianco P, Robey PG 2001 Renal phosphate wasting in fibrous dysplasia of bone is part of a generalized renal tubular dysfunction similar to that seen in tumor-induced osteomalacia. *J Bone Miner Res* 16:806–813
- Yamamoto T, Miyamoto K, Ozono K, Taketani Y, Katai K, Miyauchi A, Shima M, Yoshikawa H, Yoh K, Takeda E, Okada S 2001 Hypophosphatemic

- rickets accompanying McCune-Albright syndrome: evidence that a humoral factor causes hypophosphatemia. *J Bone Miner Metab* 19:287–295
- Ozaki T, Sugihara M, Nakatsuka Y, Kawai A, Inoue H 1996 Polyostotic fibrous dysplasia. A long-term follow up of 8 patients. *Int Orthop* 20:227–232
- Stephenson RB, London MD, Hankin FM, Kauer H 1987 Fibrous dysplasia. An analysis of options for treatment. *J Bone Joint Surg Am* 69:400–409
- Chapurlat RD, Delmas PD, Liens D, Meunier PJ 1997 Long-term effects of intravenous pamidronate in fibrous dysplasia of bone. *J Bone Miner Res* 12:1746–1752
- Yamamoto T, Ozono K, Kasayama S, Yoh K, Hiroshima K, Takagi M, Matsumoto S, Michigami T, Yamaoka K, Kishimoto T, Okada S 1996 Increased IL-6-production by cells isolated from the fibrous bone dysplasia tissues in patients with McCune-Albright syndrome. *J Clin Invest* 98:30–35
- Marie PJ, de Pollak C, Chanson P, Lomri A 1997 Increased proliferation of osteoblastic cells expressing the activating Gs  $\alpha$  mutation in monostotic and polyostotic fibrous dysplasia. *Am J Pathol* 150:1059–1069
- Riminucci M, Fisher LW, Shenker A, Spiegel AM, Bianco P, Gehron Robey P 1997 Fibrous dysplasia of bone in the McCune-Albright syndrome: abnormalities in bone formation. *Am J Pathol* 151:1587–1600
- Pfeilschifter J, Ziegler R 1998 Effect of pamidronate on clinical symptoms and bone metabolism in fibrous dysplasia and McCune-Albright syndrome. *Med Klin* 93:352–359
- Lala R, Matarazzo P, Bertelloni S, Buzi F, Rigon F, de Sanctis C 2000 Pamidronate treatment of bone fibrous dysplasia in nine children with McCune-Albright syndrome. *Acta Paediatr* 89:188–193
- Zacharin M, O'Sullivan M 2000 Intravenous pamidronate treatment of polyostotic fibrous dysplasia associated with the McCune Albright syndrome. *J Pediatr* 137:403–409
- Candeliere GA, Roughley PJ, Glorieux FH 1997 Polymerase chain reaction-based technique for the selective enrichment and analysis of mosaic *arg201* mutations in Gs  $\alpha$  from patients with fibrous dysplasia of bone. *Bone* 21: 201–206
- Terpstra L, Rauch F, Plotkin H, Travers R, Glorieux FH 2002 Bone mineralization in polyostotic fibrous dysplasia: histomorphometric analysis. *J Bone Miner Res* 17:1949–1953
- Cole DE, Fraser FC, Glorieux FH, Jequier S, Marie PJ, Reade TM, Scriver CR 1983 Panostotic fibrous dysplasia: a congenital disorder of bone with unusual facial appearance, bone fragility, hyperphosphatasemia, and hypophosphatemia. *Am J Med Genet* 14:725–735
- Bleck EE 1981 Nonoperative treatment of osteogenesis imperfecta: orthotic and mobility management. *Clin Orthop* 159:111–122
- Glorieux FH, Bishop NJ, Plotkin H, Chabot G, Lanoue G, Travers R 1998 Cyclic administration of pamidronate in children with severe osteogenesis imperfecta. *N Engl J Med* 339:947–952
- D'Amour P, Labelle F, Lecavalier L, Plourde V, Harvey D 1986 Influence of serum Ca concentration on circulating molecular forms of PTH in three species. *Am J Physiol* 251:E680–E687
- Bollen AM, Eyre DR 1994 Bone resorption rates in children monitored by the urinary assay of collagen type I cross-linked peptides. *Bone* 15:31–34
- Carter DR, Bouxsein ML, Marcus R 1992 New approaches for interpreting projected bone densitometry data. *J Bone Miner Res* 7:137–145
- Faulkner RA, Bailey DA, Drinkwater DT, McKay HA, Arnold C, Wilkinson AA 1996 Bone densitometry in Canadian children 8–17 years of age. *Calcif Tissue Int* 59:344–351
- Glorieux FH, Travers R, Taylor A, Bowen JR, Rauch F, Norman M, Parfitt AM 2000 Normative data for iliac bone histomorphometry in growing children. *Bone* 26:103–109
- Parfitt AM, Drezner MK, Glorieux FH, Kanis JA, Malluche H, Meunier PJ, Ott SM, Recker RR 1987 Bone histomorphometry: standardization of nomenclature, symbols, and units. Report of the ASBMR Histomorphometry Nomenclature Committee. *J Bone Miner Res* 2:595–610
- Zeitlin L, Rauch F, Plotkin H, Glorieux FH 2002 Height and weight development during long-term therapy with cyclical intravenous pamidronate in children and adolescents with osteogenesis imperfecta types I, III and IV. *Pediatrics* 111:1030–1036
- Rauch F, Plotkin H, Zeitlin L, Glorieux FH 2003 Bone mass, size, and density in children and adolescents with osteogenesis imperfecta: effect of intravenous pamidronate therapy. *J Bone Miner Res* 18:610–614
- Bianco P, Riminucci M, Majolagbe A, Kuznetsov SA, Collins MT, Mankani MH, Corsi A, Bone HG, Wientroub S, Spiegel AM, Fisher LW, Robey PG 2000 Mutations of the *GNAS1* gene, stromal cell dysfunction, and osteomalacic changes in non-McCune-Albright fibrous dysplasia of bone. *J Bone Miner Res* 15:120–128
- Rauch F, Travers R, Plotkin H, Glorieux FH 2002 The effects of intravenous pamidronate on the bone tissue of children and adolescents with osteogenesis imperfecta. *J Clin Invest* 110:1293–1299
- Stanton RP, Hobson GM, Montgomery BE, Moses PA, Smith-Kirwin SM, Funanage VL 1999 Glucocorticoids decrease interleukin-6 levels and induce mineralization of cultured osteogenic cells from children with fibrous dysplasia. *J Bone Miner Res* 14:1104–1114
- Fraser WD, Walsh CA, Birch MA, Durham B, Dillon JP, McCreavy D, Gallagher JA 2000 Parathyroid hormone-related protein in the aetiology of fibrous dysplasia of bone in the McCune Albright syndrome. *Clin Endocrinol (Oxf)* 53:621–628