

The Gene for Cherubism Maps to Chromosome 4p16

Valdenize Tiziani,^{1,*} Ernst Reichenberger,^{1,*} Celso Luiz Buzzo,² Sadia Niazi,¹ Naomi Fukai,¹ Michael Stiller,³ Hartmut Peters,⁴ Francisco M. Salzano,⁵ Cassio M. Raposo do Amaral,² and Bjorn Reino Olsen¹

¹Department of Cell Biology, Harvard Medical School and Harvard-Forsyth Department of Oral Biology, Harvard School of Dental Medicine, Boston; ²Instituto de Cirurgia Plástica Craniofacial-SOBRAPAR, Campinas, Brazil; ³Klinik u. Polyklinik für Zahn-Mund-und Kieferheilkunde, Freie Universität Berlin; ⁴Institut für Medizinische Genetik, Universität zu Berlin; and ⁵Departamento de Genética, Universidade Federal do Rio Grande do Sul, Porto Alegre, Brazil

Summary

Cherubism is an autosomal dominant disorder that may be related to tooth development and eruption. It is a disorder of age-related bone remodeling, mostly limited to the maxilla and the mandible, with loss of bone in the jaws and its replacement with large amounts of fibrous tissue. We have used a genomewide search with a three-generation family and have established linkage to chromosome 4p16. Three other families affected with cherubism were also genotyped and were mapped to the same locus. The combined LOD score is 4.21 at a recombination fraction of 0, and the locus spans an interval of ~22 cM.

Introduction

Cherubism (CBM; MIM 11840) is characterized by a loss of bone, restricted to the jaws, and by the replacement of this bone with fibrous tissue. As first described by Jones (1933), patients with CBM show symmetrical, hard, and painless swelling of the jaws in childhood. The involvement of the infraorbital rim and the orbital floor leads to the upward tilting of the eyeballs and consequent exposure of the inferior part of the sclerae. This gives the child a "cherubic" look, like that in Renaissance portrayals of angels. Submandibular lymph-node enlargement is often reported. In addition to the aesthetic deformity and its psychological consequences, functional impairment includes mastication and speech problems (Faircloth et al. 1991), tooth alterations, and loss of

normal vision (Marck and Kudryk 1992). The onset of the disease is usually at 14 mo–4 years of age. It progresses through puberty, then stabilizes and, remarkably, in some cases regresses without treatment (Katz et al. 1992; Timosca 1996).

The characteristic radiographic findings in CBM are well-defined multilocular areas of diminished density, often very extensive, with a few irregular bony septa. In the adult, the multilocular rarefactions become replaced by sclerosis, with progressive calcification (Cornelius and McClendon 1969).

No studies of the cellular and molecular basis for CBM are available. To understand the pathogenic mechanisms that are involved in the bone resorption and deposition of fibrous tissue in the jaws, we selected a genetic approach. As a basis for gene identification, we have determined the chromosomal locus for the cherubism gene. Here we describe clinical findings in a three-generation family affected with cherubism and in a genomewide search to find linkage. The linkage data were confirmed in three other families.

Subjects and Methods

Families

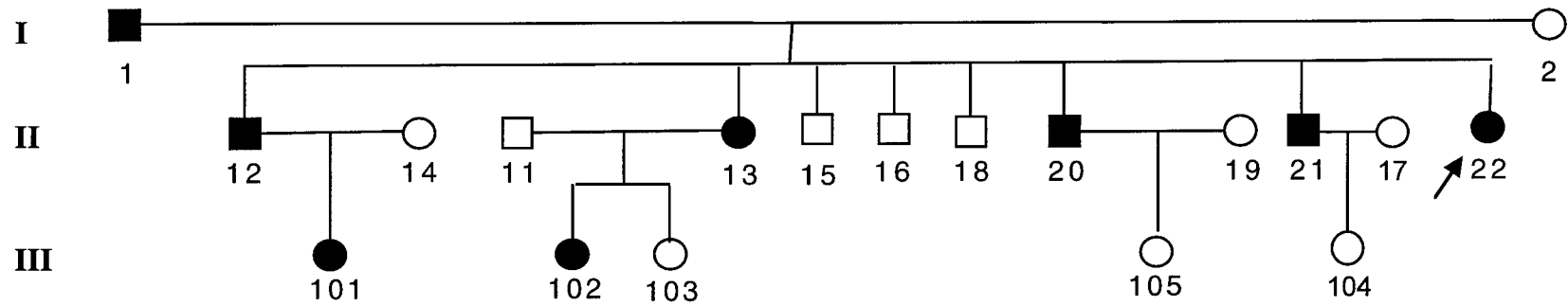
During the past 2 years, we have encountered 15 patients (10 males and 5 females) from four families with CBM. Families were referred by clinicians in Brazil and Germany (families A and D—Instituto de Cirurgia Plástica Craniofacial, SOBRAPAR, Brazil, Dr. Cassio M. Raposo do Amaral; family B—Universidade Federal do Rio Grande do Sul, Brazil, Dr. Francisco M. Salzano; family C—Universität zu Berlin, Institut für Medizinische Genetik, Dr. Hartmut Peters). The clinical investigators were responsible for explaining the research to the families and obtaining their informed consent, in accordance with their local institutional review boards. The study was approved by the Harvard Medical School and the Forsyth Dental Center review boards. Peripheral blood samples (3–5 ml) were collected and shipped to Boston.

Received January 20, 1999; accepted for publication April 28, 1999; electronically published May 21, 1999.

Address for correspondence and reprints: Dr. Valdenize Tiziani, 140 The Fenway, Boston, MA 02115. E-mail: vtiziani@warren.med.harvard.edu

*These authors contributed equally to this study.

© 1999 by The American Society of Human Genetics. All rights reserved. 0002-9297/99/6501-0021\$02.00



D4S3038	3 2	3 3	3 1	1 3	4 6	3 6	4 5	3 5	2 5	2 5	2 3	3 5	3 4	2 4	3 5	3 3	3 5
D4S2936	4 7	4 1	4 6	6 6	3 7	4 7	3 6	4 6	6 7	6 7	1 7	4 6	4 6	6 6	4 6	4 1	1 6
D4S1614	3 5	3 5	3 2	3 2	4 5	3 4	1 5	3 1	1 5	1 5	5 5	3 1	1 5	5 5	3 1	3 1	1 5
D4S432	6 2	6 2	6 4	4 4	1 3	6 3	1 1	6 1	1 2	1 2	2 3	6 1	1 5	2 5	6 1	6 3	1 3
D4S3023	2 2	2 1	2 5	3 5	1 1	2 1	1 3	2 3	2 3	2 3	1 2	2 3	3 3	3 4	2 3	2 1	1 3
D4S2935	2 2	2 2	2 2	2 6	1 2	2 1	1 6	2 6	2 6	2 6	2 2	2 6	2 6	2 6	2 6	2 2	2 6
D4S3007	2 4	2 2	2 2	2 3	2 4	2 4	1 4	2 1	1 4	1 4	2 4	2 2	2 4	4 4	2 1	2 2	1 2
D4S394	3 3	3 4	3 3	2 3	1 3	3 3	3 3	3 3	3 3	3 3	3 4	3 4	1 4	1 5	3 3	3 4	3 4
D4S3009	1 3	1 2	1 3	4 3	1 3	1 3	3 3	1 3	3 3	3 3	2 3	1 2	2 3	3 4	1 3	1 2	2 3
D4S1582	1 4	1 4	1 4	4 4	1 1	1 1	1 1	1 1	1 4	1 4	4 4	1 4	4 5	1 5	1 1	1 4	1 4
D4S2928	3 4	3 4	3 3	3 3	2 3	3 3	3 4	3 4	4 4	4 4	4 4	3 4	1 4	1 3	3 4	3 4	4 4
D4S2949	4 2	4 5	4 3	3 3	3 4	4 4	4 4	4 4	2 4	2 4	2 5	4 5	2 5	1 2	2 4	4 5	4 5
D4S2942	1 2	1 3	1 3	3 4	1 4	1 1	1 4	1 4	2 4	2 4	2 3	1 3	-	-	2 4	1 4	3 4
D4S403	4 1	4 1	4 4	1 4	2 3	4 2	2 3	4 3	1 3	1 3	1 1	4 1	-	-	1 3	4 3	1 3
D4S1567	5 2	5 4	5 4	4 1	3 5	5 3	3 4	5 4	2 4	2 4	2 4	5 4	-	-	2 4	5 4	4 4

Figure 1 Pedigree of family A affected with CBM. Haplotypes for each family member are listed below the pedigrees. The most likely haplotypes for the linked allele are indicated as boxed areas. The arrow indicates the proband II-22.

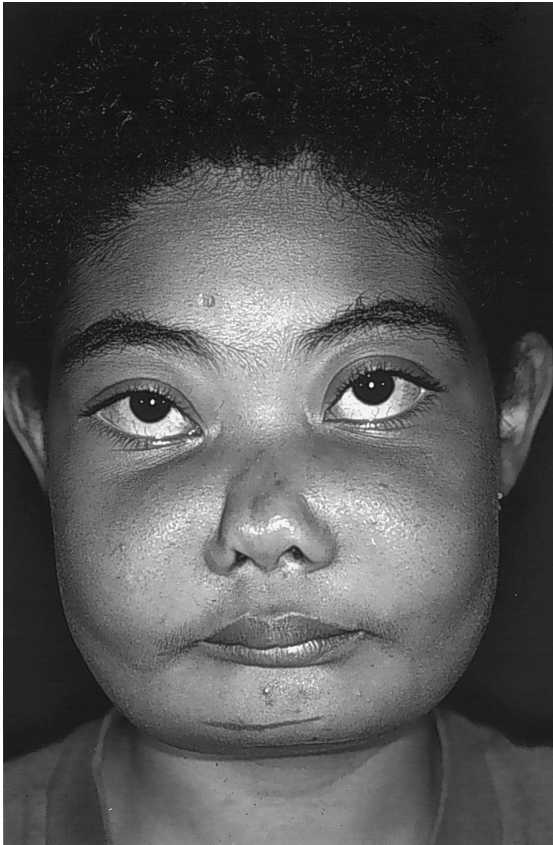

Figure 2 Proband of family A

Genotyping

DNAs were isolated from the blood samples (Puregene; Gentra Systems) and polymorphic microsatellite markers (short-sequence-repeat polymorphisms [SSRPs]) were selected (Dib et al. 1996) and purchased

from Research Genetics. PCR amplification of genomic DNA was performed in a 10- μ l volume containing 10 ng of template DNA and 4 pmol of each primer. The forward primers were end-labeled with γ [33 P]-ATP. Conditions for PCR included an initial denaturation step at 95°C for 4 min, followed by 29 cycles at 94°C for 40 s, 56°C for 50 s, 72°C for 50 s, with a final extension at 72°C for 10 min. PCR products were denatured at 95°C for 5 min in the presence of 40% formamide. Aliquots (2.5 μ l) were separated on denaturing polyacrylamide gels; this was followed by autoradiography.

Linkage analysis

Pairwise linkage analysis between the disease locus and each of the marker loci, was performed by the MLINK program of the LINKAGE package (Lathrop et al. 1985), under the assumptions of a disease-gene frequency of 0.1%, equal allele frequency, full penetrance, autosomal dominant inheritance, and equal recombination rates for males and females.

Histology

Samples of affected tissues were collected from the proband and were fixed in 4% paraformaldehyde in PBS for 24 h. The samples were washed and were immersed in 20% sucrose/PBS and were shipped to Boston. Decalcification was performed in 10% formic acid, which was changed every other day for 2 wk, on a shaker. The samples were dehydrated in two 30-min changes of 70% ethanol, followed by one 30-min change each of 90% and 95% ethanol. This was followed by three 30-min changes of 100% ethanol. The tissue was then immersed in three 30-min changes of xylene, followed by a 1:1 solution of xylene/wax, and was left overnight at 60°C. Subsequently, the tissue was immersed in three 1-h

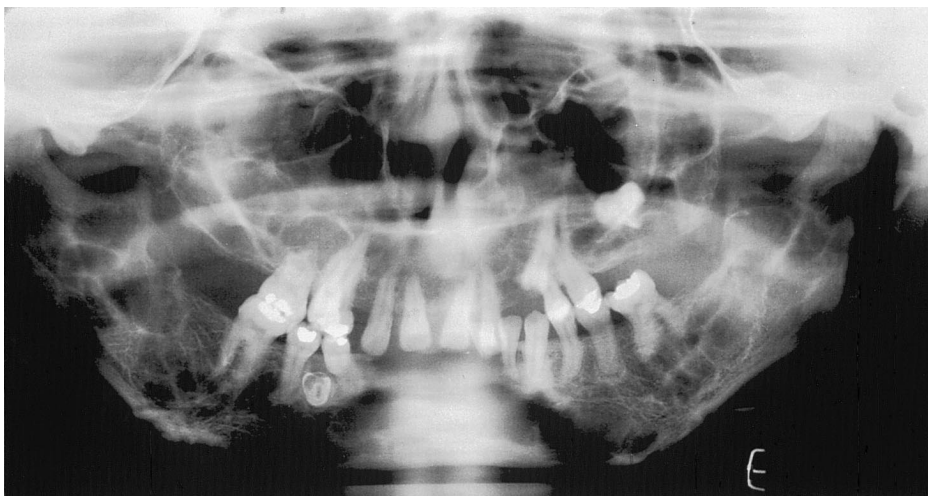


Figure 3 Multilocular radiolucencies observed on orthopantomograph of proband

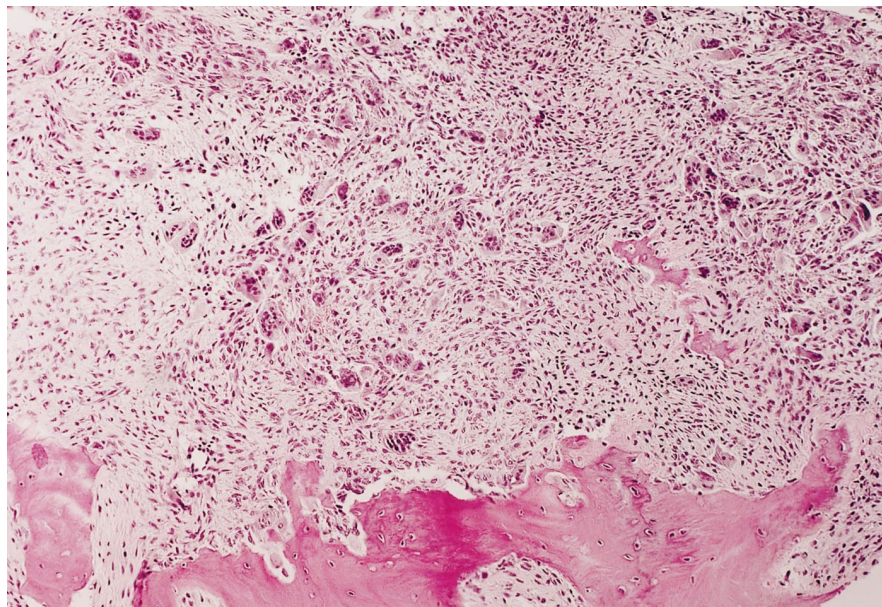


Figure 4 Photomicrograph showing presence of multiple osteoclast-like cells within both cellular and fibrous tissue and bone fragment, in biopsy of maxilla of proband (II-22) of family A ($\times 100$).

changes of paraffin at 60°C, followed by embedding in paraffin. Sections (7 mm) were made and were stained with hematoxylin and eosin, were mounted in Permount, and were analyzed by light microscopy.

Results

Clinical Findings

The evaluation of the proband (patient II-22) led us to a three-generation family (family A), with eight affected individuals—four males and four females (fig. 1)—displaying the CBM phenotype. Individuals within the family were considered affected with CBM when they presented clinical history of enlargement of maxilla and/or mandible, with onset in childhood and/or radiographic evidence of multilocular radiolucencies in the jaws.

The proband, patient II-22 (fig. 2) is a 14-year-old female with maxillary enlargement that started at age 5 years and has that has continued to date. The palatal vault is obliterated because of bone overgrowth. Radiographic multilocular radiolucencies (fig. 3), enlarged submandibular lymph nodes, and numerous dental anomalies were noted on both clinical and radiographic examination. Histological analysis of lesion tissue showed the presence of multiple osteoclast-like cells in a fibrous and cellular stroma (fig. 4). Radiographs from the whole body failed to show any other bone alteration. A cytogenetic study did not show any chromosomal abnormalities. Both analysis of blood cells, proteins, and ions (including parathyroid hormone, calcitonin, and

calcium) and coagulation tests failed to identify any abnormalities. Analysis of urinary constituents was also normal. These findings are all consistent with the diagnosis of cherubism.

For family A, the mandible in males was more severely affected than the maxilla, whereas in females the maxilla was more severely affected. On average, the clinical onset of the disease was earlier in females (5.5 years of age) than in males (10.6 years of age) (table 1).

Assignment of the CBM Gene to Chromosome 4p

We have mapped the locus for CBM by means of DNA from family A (fig. 1). Traditional linkage analysis (Morton 1955; Dracopoli 1995) was first used to exclude several potential candidate gene loci. After excluding candidate-gene regions on chromosomes 6, 7, 9, 11, 12, 18, and 20, we switched to random mapping of the entire genome, using a set of 360 polymorphic microsatellite markers (Dib et al. 1996) separated by an average distance of 10 cM.

Under the assumption of full penetrance, simulation showed a maximum LOD score of 3.31 (recombination fraction $[\theta] 0$). The haplotype analysis showed no recombination on chromosome 4p, for markers D4S1614, D4S432, D4S3023, D4S2935, D4S3007, D4S394, D4S3009, D4S1582, and D4S2928. Maximum LOD scores (Z_{max}) were obtained for markers D4S1614, D4S432, and D4S2928 ($Z_{max} = 3.31$).

By the same approach and methods, three other families (families B–D) were also analyzed. Haplotypes for the three families showed no conflict with the data for

Table 1**Presentation of the Disorder in the Affected Members of Family A**

PATIENT	SEX	AGE AT EXAM (YEARS)	ENLARGEMENT		RADIOGRAPHIC EVIDENCE		AGE AT ONSET (YEARS)
			Mandible	Maxilla	Mandible	Maxilla	
II-22	Female	14	+	++++	Yes	Yes	5
II-13	Female	31	+	+	Yes	Yes	6
II-101	Female	8	+	++	Yes	Yes	6
II-102	Female	9	+	+++	Yes	Yes	5
I-1	Male	56	+ *	...	Yes	No	12
I-20	Male	24	+ *	...	Yes	Yes	6
II-21	Male	23	+ **	...	Yes	Yes	14
II-12	Male	32	Yes	Yes	...

* Asymmetry of the mandible, because of previous surgery.

** Asymmetry of the mandible, because of enlargement only of the left side.

+ =Mild enlargement; ++ =moderate enlargement; +++ =severe enlargement; ++++ =very severe enlargement.

family A, and the LOD scores were positive for all of them. The combined LOD score for pedigrees A–D is 4.21 ($\theta = 0$) (table 2). The locus spans an interval of ~22 cM, according to the Généthon human linkage map (Dib et al. 1996).

Family B (fig. 5) has been described elsewhere (Salzano and Ebling 1966) and is composed of five members in two generations. Both affected individuals are males. The disease in this family shows linkage to the locus established in family A, with no recombination for several markers between D4S2957 and D4S2949. $Z_{max} = 0.60$ ($\theta = 0$) for markers D4S1582, D4S394, and D4S2949.

Family C (fig. 5) consists of five members in three generations, including three affected males. The disease in this family shows linkage to chromosome 4, with $Z_{max} = 0.30$ ($\theta = 0$) for markers D4S394, D4S2935, D4S1582, and D4S2949.

Family D (fig. 5) consists of four members in two generations, including one affected male and one affected female. The disease in this family shows linkage to the same locus on chromosome 4, with $Z_{max} = 0.30$ ($\theta = 0$) for markers D4S3038, D4S1614, D4S432, and D4S394.

Discussion

Linkage of the cherubism locus was assigned to chromosome 4p16 on the basis of data from family A. Haplotype-analysis data from families B–D are supportive of this linkage, although by themselves the LOD scores for these families (0.60, 0.30, and 0.30 respectively) would not be sufficient for assignment of linkage.

Affected members of the four families included in this study show, in most cases, the typical characteristics of CBM. However, our observations differ from previous reports with regard to sex differences in expressivity and to penetrance of the disorder. Variable expressivity is

reported for CBM, with 100% penetrance in males and reduced penetrance in females—50%–70%—(Anderson and McClendon 1962). In family A, however, reduced penetrance in females was not observed. In fact, the males of this family had a milder expression of the disease than was seen in the females. One of the affected males (II-12) was diagnosed as affected on the basis of radiographic evidence only, and he had no physical signs of the disease.

For family A, the linkage data suggest that the locus spans the interval between markers D4S2936 and D4S2949. A critical individual in this family is the child III-105. At this time, she is 2.5 years old, with no clinical signs of the disease. Her radiographs show some dental abnormalities that may not be related to the disease, since her unaffected mother also presented with some dental anomalies. Another clinical finding in this child, however, was a preauricular appendage, a feature present in her 23-year-old affected uncle, family member II-21. The presence of a preauricular appendage has not been previously reported as a characteristic feature of CBM, but we cannot exclude the possibility that it is associated with CBM in this family. The child III-105 shows a breakpoint between markers D4S2936 and D4S1614. If we assume that she is not affected, then the locus is defined as being between markers D4S2936 and D4S2949. Recombinations in families B and D restrict the locus further, to an interval of ~21 cM between markers D4S2936 and D4S1582. Should future analyses indicate that subject III-105 is affected, the locus for the CBM gene would be on the telomeric side of D4S2936.

At present, however, the most reasonable conclusion from the linkage data on all four families is that the locus for CBM is located on the telomeric side of D4S1582. A total of 1.65 Mb from 4p16 has been sequenced in the course of identification of the Huntington disease gene (Zuo et al. 1993). Many disorders—such as achondroplasia (MIM 100800; Shiang et al. 1994;

Table 2**LOD Scores between CBM Locus and Chromosome 4p Markers**

LOCUS AND FAMILY	LOD SCORES AT $\theta = 0$						
	0	0.01	0.05	0.1	0.2	Z_{\max}	θ_{\max}
D4S3038:							
A	$-\infty$.96	1.48	1.55	1.34	1.55	.1
B	-.81	-.72	-.50	-.33	-.15	-.15	.2
C
D	.3	.29	.25	.21	.13	.3	0
D4S2936:							
A	$-\infty$	1.26	1.76	1.80	1.54	1.80	.07
B	$-\infty$	-1.34	-.67	-.40	-.16	-.16	.2
C	0	0	0	0	0	0	0
D
D4S1614:							
A	3.31	3.25	3.04	2.76	2.14	3.31	0
B
C	0	0	0	0	0	0	0
D	.3	.29	.25	.21	.13	.3	0
D4S432:							
A	3.31	3.25	3.04	2.76	2.14	3.31	0
B	.30	.29	.25	.21	.13	.3	0
C	0	0	0	0	0	0	0
D	.30	.29	.25	.21	.13	.3	0
D4S3023:							
A	1.20	1.18	1.11	1.02	.81	1.20	0
B	-.81	-.72	-.50	-.33	-.15	-.15	.2
C	0	0	0	0	0	0	0
D	0	0	0	0	0	0	0
D4S2935:							
A	.60	.59	.55	.51	.40	.60	0
B	.56	.55	.48	.40	.23	.56	0
C	.30	.29	.27	.25	.20	.30	0
D	0	0	0	0	0	0	0
D4S3007:							
A	2.70	2.66	2.48	2.25	1.74	2.70	0
B	-.54	-.50	-.37	-.26	-.12	-.12	.2
C	0	0	0	0	0	0	0
D	0	0	0	0	0	0	0
D4S394:							
A	.60	.59	.55	.51	.40	.60	0
B	.60	.58	.51	.42	.25	.60	0
C	.30	.29	.27	.25	.20	.30	0
D	.30	.29	.25	.21	.13	.30	0
D4S3009:							
A	3.01	2.96	2.76	2.50	1.94	3.01	0
B	-.54	-.50	-.37	-.26	-.12	-.12	.2
C	0	0	0	0	0	0	0
D	0	0	0	0	0	0	0
D4S1582:							
A	1.20	1.17	1.05	.89	.57	1.20	0
B	.60	.58	.51	.42	.25	.60	0
C	.30	.29	.27	.25	.20	.30	0
D	∞	-1.4	-.72	-.44	-.19	-.19	.2
D4S2928:							
A	3.31	3.25	3.04	2.76	2.14	3.31	0
B	.30	.29	.25	.21	.13	.30	0
C	0	0	0	0	0	0	0
D	0	0	0	0	0	0	0
D4S2949:							
A	$-\infty$.66	1.20	1.29	1.13	1.29	.1
B	.60	.58	.51	.42	.25	.60	0
C	.30	.29	.27	.25	.20	.30	0
D	∞	-1.4	-.72	-.44	-.19	-.19	.2

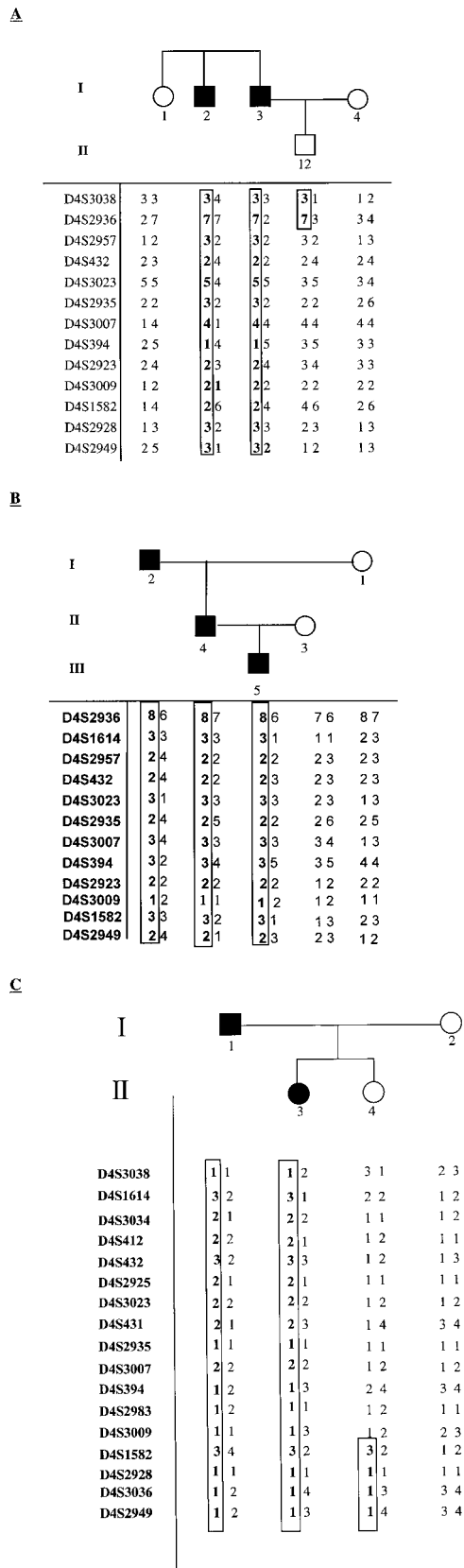


Figure 5 Pedigrees of families B (A), C (B), and D (C) affected with CBM. Haplotypes for each available family member are listed below the pedigree. Boxed areas indicate the most likely alleles.

Rousseau et al. 1994), hypochondroplasia (MIM 146000; Bellus et al. 1995; Stoilov et al. 1995) and Crouzon syndrome (MIM 123500) with acanthosis nigricans (Meyers et al. 1995)—are all caused by mutations in the FGFR3 gene that map to chromosome 4p16. Both congenital stationary type 3 nightblindness (Gal et al. 1994) and a subset of recessive retinitis pigmentosa (McLaughlin et al. 1993) are caused by mutations in PDE6B (MIM 180072), the most telomeric gene described on chromosome 4.

According to Jones (1965), typical cases of cherubism do not involve bones other than the maxilla and mandible. A few reports describe signs in other bones, such as rarefaction or cystlike changes in the ribs (Wayman 1978) and the humerus (Thompson 1962). In the families described here, however, we did not find any evidence of other bones being affected. Radiographic exams of the whole body were performed for the proband of family A, and no alterations were detected in other bones. We conclude, therefore, that CBM in the families that we studied is a localized disorder restricted to the jaws. Considering that the bones of the jaws house the developing teeth, one interesting possibility is that the disorder may be related to the development of the permanent dentition (Jones 1965).

In patients with CBM, teeth may be displaced, unerupted, unformed, or absent or may appear to be floating in cystlike spaces. Malocclusion, premature exfoliation of deciduous teeth, and root resorption have also been reported (McClendon et al. 1962). The disease does not seem to be an early developmental disorder, since children are born with no signs of the disease and usually do not express any symptoms until several years after birth. The disease develops in a time frame coinciding with many different events of tooth development, particularly the eruption of the permanent dentition, and the most dramatic expression of the disorder is seen at age 5–15 years. Therefore, the tooth abnormalities may indeed be related to the genetic causes of cherubism. In family A, agenesis of teeth was present in two severely affected females.

CBM has been reported in association with mosaicism for both expansion and deletion of the FMR1 gene, with clinical symptoms of mental retardation, prominent forehead, and macroorchidism (Quan et al. 1995). Association of CBM with Noonan syndrome has also been reported (MIM 163955; Dunlap et al. 1989). But finding the locus for CBM on chromosome 4 confirms a suggestion by Cohen and Gorlin (1991) that these disorders are indeed different entities, since Noonan syndrome has been mapped to chromosome 12 (Jamieson et al. 1994). CBM, in association with gingival fibromatosis, has been given the designation “Ramon syndrome” (MIM 266270; Ramon et al. 1967). One family has been described with Ramon syndrome and juvenile rheumatoid

arthritis (de Pina-Neto et al. 1986, 1998). Ramon syndrome has not yet been mapped, and it will be interesting to test for linkage to the CBM locus.

Bone homeostasis reflects the balance between bone formation by osteoblasts and bone resorption by osteoclasts. In CBM there is excessive bone resorption restricted to the maxilla and mandible. Physical contact with osteoblasts or marrow stromal cells is required for osteoclast differentiation, and recent findings have led to the identification of what are likely to be the molecular mediators of this contact-dependent process. RANK, a cell-surface receptor on osteoclast-progenitor cells (Anderson et al. 1997), interacts with RANKL/TRANCE, which appears to be identical to an osteoblast/stromal cell-associated factor called "osteoclast differentiation factor" (ODF) (Wong et al. 1997; Yasuda et al. 1998). A soluble factor called "osteoclastogenesis-inhibitory factor" (OCIF), with homology to osteoprotegerin (OPG), can block the interaction between RANK and RANKL, thereby inhibiting osteoclast differentiation (Simonet et al. 1997). In CBM, localized down-regulation of a factor such as OPG could account for the increase in osteoclast differentiation and could cause excessive bone resorption in the maxilla and mandible.

The mutation causing CBM could be a factor involved in the regulation of any of the genes regulating bone formation or resorption, including CBFA1 (Mundlos et al. 1997), RANK (Anderson et al. 1997), RANKL/TRANCE/ODF (Wong et al. 1997; Yasuda et al. 1998) and OPG/OCIF (Simonet et al. 1997). However, none of these genes implicated in osteoblast and osteoclast differentiation/function are mapped to chromosome 4p. It is likely, therefore, that identifying the gene for CBM will provide novel insights into bone homeostasis. It may also have therapeutic consequences. At present there is no rational treatment for CBM. In severe cases, when there is functional and aesthetic impairment, surgical intervention is necessary (Kaugars et al. 1992). Thus, identification of the CBM gene not only should contribute significantly to the understanding of bone resorption and formation in the mandible and maxilla but may also help in the design of an effective therapy.

Acknowledgments

This work would not have been possible without the cooperation of the families themselves and of the staff of the clinical institutions involved, especially Instituto de Cirurgia Plastica Craniofacial SOBRAPAR. We are particularly grateful to nurse Leda A. A. Turchiari and to Drs. Ana Cristina S. Rossi, William McLean, and Jose Michel Kalaf, for their invaluable assistance in collecting and analyzing patient data, and to Dr. Walter Pinto Jr. for the cytogenetic examination of the proband (family A). The authors are also thankful to Susan Orlando, the librarian of Forsyth Dental Center. The research was sup-

ported in part by National Institute of Health grant AR36819, Fundação de Amparo à Pesquisa do Estado de São Paulo processo 95/41447, Financiadora de Estudos e Projetos processo 4395036900, Programa de Apoio a Núcleos de Excelência, Conselho Nacional de Desenvolvimento Científico e Tecnológico, and Fundação Coordenação de Aperfeiçoamento de Pessoal de Nível Superior processo 1808/95-3.

Electronic-Database Information

Accession numbers and URLs for data in this article are as follows:

Online Mendelian Inheritance in Man (OMIM), <http://www.ncbi.nlm.nih.gov/Omim> (for cherubism [MIM 11840], Ramon syndrome [MIM 266270], Noonan-like/multiple giant cell-lesion syndrome [MIM 163955]), achondroplasia [MIM 100800], hypochondroplasia [MIM 146000], phosphodiesterase 6B [MIM 180072], and Crouzon syndrome [MIM 123500])

References

- Anderson DE, McClendon JL (1962) Cherubism: hereditary fibrous dysplasia of the jaws. I. Genetic considerations. *Oral Surg Oral Med Oral Pathol* 15:5-16
- Anderson DM, Maraskovsky E, Billingsley WL, Dougall WC, Tometsko ME, Roux ER, Teepe MC, et al (1997) A homologue of the TNF receptor and its ligand enhance T-cell growth and dendritic-cell function. *Nature* 390:175-179
- Bellus GA, McIntosh I, Smith EA, Aylsworth AS, Kaitila I, Horton WA, Greenhaw GA, et al. (1995) A recurrent mutation in the tyrosine kinase domain of fibroblast growth factor receptor 3 causes hypochondroplasia. *Nat Genet* 10:357-359
- Cohen M, Gorlin RJ (1991) Noonan-like/multiple giant cell lesion syndrome. *Am J Med Genet* 40:159-166
- Cornelius GA, McClendon JL (1969) Cherubism—hereditary fibrous dysplasia of the jaws—roentgenographic features. *Am J Roentgenol Radium Ther Nucl Med* 106:136-143
- De Pina-Neto JM, Moreno AFC, Silva LR, Velludo MASL, Ribeiro MVM, Athayde-Junior L, Voltarelli JC (1986) Cherubism, gingival fibromatosis, epilepsy, and mental deficiency (Ramon syndrome) with juvenile rheumatoid arthritis. *Am J Med Genet* 25:433-441
- De Pina-Neto JM, Vieira de Souza N, Velludo MASL, Perosa GBD, de Freitas MMS, Colafemina JF (1998) Retinal changes and tumorigenesis in Ramon syndrome: follow-up of a Brazilian family. *Am J Med Genet* 77:43-46
- Dib C, Faure S, Fizames C, Samson D, Drouot N, Vignal A, Millasseau P, et al (1996) A comprehensive genetic map of the human genome based on 5,264 microsatellites. *Nature* 380:152-154
- Dracopoli N C (ed) (1995) *Current protocols in human genetics*. John Wiley and Sons, Inc., New York
- Dunlap C, Neville B, Vickers RA, O'Neil D, Barker B (1989) The Noonan syndrome/cherubism association. *Oral Surg Oral Med Oral Pathol* 67:698-705
- Faircloth WJ Jr, Edwards RC, Farhood VW (1991) Cherubism

- involving a mother and daughter: case reports and review. *J Oral Maxillofac Surg* 49:535-542
- Gal A, Xu S, Piczenik Y, Eiberg H, Duvigneau C, Schwinger E, Rosenberg T (1994) Gene for autosomal dominant congenital stationary night blindness maps to the same region as the gene for the beta-subunit of the rod photoreceptor cGMP phosphodiesterase (PDEB) in chromosome 4p16.3. *Hum Mol Genet* 3:323-325
- Jamieson CR, van der Burgt I, Brady AF, van Ree M, Elsayi MM, Hol F, Jeffery S et al (1994) Mapping a gene for Noonan syndrome to the long arm of chromosome 12. *Nat Genet* 8:357-360
- Jones WA (1933) Familial multilocular cystic disease of the jaws. *Am J Cancer* 17:946-950
- (1965) Cherubism: a thumbnail sketch of its diagnosis and a conservative method of treatment. *Oral Surg Oral Med Oral Pathol* 20:648-653
- Katz JO, Dunlap CL, Annis RL (1992) Cherubism: report of a case showing regression without treatment. *J Oral Maxillofac Surg* 50:301-303
- Kaugars GE, Niamtu J III, Svirsky JA (1992) Cherubism: diagnosis, treatment, and comparison with central giant cell granulomas and giant cell tumors. *Oral Surg Oral Med Oral Pathol* 73:369-374
- Lathrop GM, Lalouel JM, Julier C, Ott J (1985) Multilocus linkage analysis in humans: detection of linkage and estimation of recombination. *Am J Hum Genet* 37:482-498
- Marck PA, Kudryk WH (1992) Cherubism. *J Otolaryngol* 21:84-87
- McClendon JL, Anderson DE, Cornelius EA (1962) Cherubism—hereditary fibrous dysplasia of the jaws II: pathologic considerations. *Oral Surg Oral Med Oral Pathol* 15:17-42
- McLaughlin ME, Sandberg MA, Berson EL, Dryja TP (1993) Recessive mutations in the gene encoding the beta-subunit of rod phosphodiesterase in patients with retinitis pigmentosa. *Nat Genet* 4:130-134
- Meyers GA, Orlow SJ, Munro IR, Przylepa KA, Jabs EW (1995) Fibroblast growth factor receptor 3 (FGFR3) transmembrane mutation in Crouzon syndrome with acanthosis nigricans. *Nat Genet* 11:462-464
- Morton NE (1955) Sequential tests for the detection of linkage. *Am J Hum Genet* 7:277-318
- Mundlos S, Otto F, Mundlos C, Mulliken JB, Aylsworth AS, Albright S, Lindhout D, et al (1997) Mutations involving the transcription factor CBFA1 cause cleidocranial dysplasia. *Cell* 89:773-779
- Quan F, Grompe M, Jakobs P, Popovich BW (1995) Spontaneous deletion in the *FMR1* gene in a patient with fragile X syndrome and cherubism. *Hum Mol Genet* 4:1681-1684
- Ramon Y, Berman W, Bubis JJ (1967) Gingival fibromatosis combined with cherubism. *Oral Surg* 24:436-448
- Rousseau F, Bonaventure J, Legeai-Mallet L, Pelet A, Rozet J-M, Maroteaux P, Le Merrer M, et al (1994) Mutations in the gene encoding fibroblast growth factor receptor-3 in achondroplasia. *Nature* 371:252-254
- Salzano FM, Ebling H (1966) Cherubism in a Brazilian kindred. *Acta Genet Med Gem* 15:296-301
- Shiang R, Thompson LM, Zhu YZ, Church DM, Fielder TJ, Bocian M, Winokur ST et al. (1994) Mutations in the transmembrane domain of *FGFR3* cause the most common genetic form of dwarfism, achondroplasia. *Cell* 78:335-342
- Simonet WS, Lacey DL, Dunstan CR, Kelley M, Chang MS, Luthy R, Nguyen HQ, et al (1997) Osteoprotegerin: a novel secreted protein involved in the regulation of bone density. *Cell* 89:309-319
- Stoilov I, Kilpatrick MW, Tsipouras PA (1995) A common *FGFR3* gene mutation is present in achondroplasia but not in hypochondroplasia. *Am J Med Genet* 55:127-133
- Thompson ER (1962) Multiple giant cell tumors—report of a case. *Oral Surg Oral Med Oral Pathol* 15:69-73
- Timosca GC (1996) Cherubism: regression of the lesions and spontaneous bone regeneration. *Rev Stomatol Chir Maxillofac* 97:172-177
- Wayman JB (1978) Cherubism: a report on three cases. *Br J Oral Surg* 16:47-56
- Wong BR, Josien R, Lee SY, Sauter B, Li HL, Steinman RM, Choi Y (1997) TRANCE (tumor necrosis factor [TNF]-related activation-induced cytokine), a new TNF family member predominantly expressed in T cells, is a dendritic cell-specific survival factor. *J Exp Med* 186:2075-2080
- Yasuda H, Shima N, Nakagawa N, Yamaguchi K, Kinosaki M, Mochizuki SI, Tomoyasu A, et al (1998) Osteoclast differentiation factor is a ligand for osteoprotegerin/osteoclastogenesis-inhibitory factor and is identical to TRANCE/RANKL. *Proc Natl Acad Sci USA* 95:3597-3602
- Zuo J, Robbins C, Baharloo S, Cox DR, Myers RM (1993) Construction of cosmid contigs and high-resolution restriction mapping of the Huntington disease region of human chromosome 4. *Hum Mol Genet* 2:889-899

